

532 nm Subthreshold MicroPulse Effectively Reduces Diabetic Macular Edema after Failed Conventional Laser Treatment



David D. Gossage, DO, FAOCO, FAAO, is medical director of the Gossage Eye Institute in Hillsdale, Mich. He is also Clinical Assistant Professor of Ophthalmology in the Department of Specialty Medicine at the Ohio University Heritage College of Osteopathic Medicine in Athens, Ohio, and Clinical Associate Professor of Ophthalmology at Michigan State University in East Lansing, Mich.

History and examination

This case involves a 75-year-old pseudophakic woman with Type 2 diabetes mellitus. Her left eye was treated in 2004 and 2008 with traditional focal laser treatment, which partially resolved her diabetic macular edema (DME).

By late 2011, fluorescein angiography showed a partial retinal vein occlusion with background diabetic retinopathy and worsening macular edema. Optical coherence tomography (OCT) demonstrated a central retinal thickness (CRT) of 434 μm , and the area just temporal to that was 445 μm (Fig 1). Visual acuity (VA) was 20/50.

Treatment

In December 2011, I treated this eye with subthreshold MicroPulse laser therapy using the IRIDEX IQ 532™ laser. To determine the power for treatment, I typically perform a continuous-wave test burn over the edematous area using 100 mW at 100 ms. I increase the power in increments of 50 mW (moving to a adjacent locations) until I see retinal whitening. In this case, retinal whitening was achieved at 100 mW; this eye was pseudophakic and had good uptake of laser energy.

For treatment, I switch the laser to MicroPulse mode at a 5% duty cycle, double the exposure time (to 200 ms) and reduce the power 70%. In this case, the power was reduced to 70 mW. Once I adjust my parameters, I apply some initial shots outside the vascular arcade to make sure there is no visible tissue reaction. Then I treat the area of edema, applying a high

density confluent application without targeting microaneurysms specifically. (See Table 1. Treatment Parameters)

Result

In March 2011, approximately three months after treatment, OCT demonstrated almost complete resolution of edema, with a decrease in CRT from 434 μm to 314 μm (Fig 2). VA improved from 20/50 to 20/30, and the patient was very pleased with the treatment results. She had less metamorphopsia, and noticed an overall, subjective improvement in her vision. There are no visible scars on the retina or thermal damage that one would expect to see following conventional, continuous-wave laser photocoagulation.

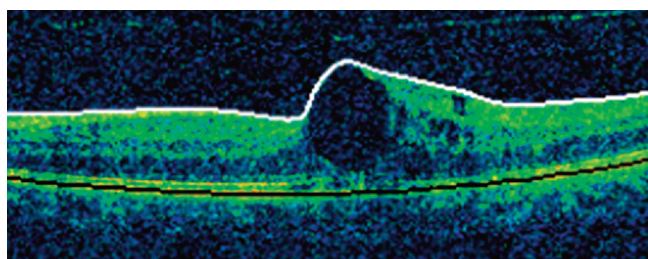
I will continue to monitor this patient to determine whether additional treatment is necessary. Her edema responded well to this treatment, so I will most likely retreat it with the MicroPulse laser if the edema returns.

Discussion and treatment pearls

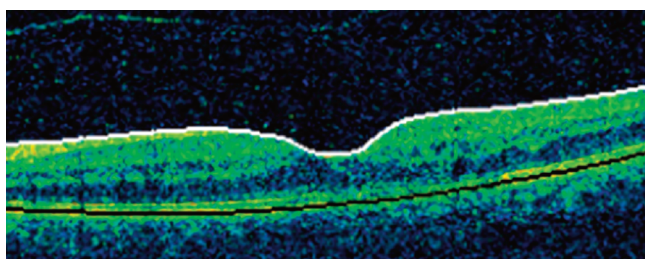
I became interested in using the MicroPulse laser for DME after reading reports of others' success with this laser. I wanted to be able to treat the retina without inducing scotomas or thermal damage that could worsen patients' vision.

Clinicians who are considering this laser will find that the learning curve is short, as the procedure is very similar to traditional photocoagulation. The biggest difference is the lack of a visible endpoint, so we first titrate to a visible endpoint using the laser in its continuous-wave mode, and then switch to the MicroPulse mode, as described above.

With subthreshold, low intensity techniques that produce only low and confined thermal elevations, there is very little lateral and axial spread of heat from the retinal pigment epithelium spots directly targeted by the laser.¹ Therefore, when performing MicroPulse laser for DME, I place more spots than one would with a traditional grid and constantly moving quickly across the areas of edema, "painting" invisible spots over the



Pre Subthreshold MicroPulse Treatment: CRT 434 μm , VA 20/50



3 Months Post Treatment: CRT 314 μm ; VA 20/30

edematous area by moving from right to left, back and forth. Next, I pattern shots up and down over the same area again, hitting the area twice until I have covered the entire edematous area. I have found that setting the laser in "auto-repeat" at a high repetition rate makes the procedure faster and easier on the patient and the physician.

Depending on the severity of the disease, I typically see patients for follow-up 6 to 12 weeks after treatment, and I generally wait 12-16 weeks after treatment to determine whether the edema is continuing to improve. If the improvement is insufficient, I make a decision about retreatment at that point. This patient had remarkable improvement at 12 weeks.

When retreating patients, I always re-titrate my settings with a continuous-wave test burn before each procedure, rather than basing treatment on a previous measurement. If the edema improved after the previous treatment, less power may be needed for the retreatment.

The IQ 532 laser offers a number of advantages in treating DME, chief among them is enabling clinicians to treat without causing thermal damage or scotomas when using the laser in its MicroPulse mode to deliver subthreshold laser treatments. Because of this, we may be able to reduce the risks inherent in frequent intravitreal injections, and we can consider earlier or more frequent laser treatment without cumulative laser damage. We can also retreat patients like the one described here who have had prior focal laser, in whom we might otherwise be concerned about causing additional damage.

**TABLE 1: TREATMENT PARAMETERS
IRIDEX IQ 532 | Diabetic Macular Edema**

Wavelength:	532 nm
Test Burn	
Mode:	Continuous-wave
Spot size on slit lamp adapter:	100 µm
Contact lens:	Mainster focal grid (laser magnification: 1.05x)
Power:	100 mW
Exposure duration:	100 ms
Technique:	Performed over the edematous area. Power is increased in increments of 50 mW (moving to adjacent locations) until I see retinal whitening.
Subthreshold MicroPulse Treatment	
Mode:	MicroPulse
Spot size on slit lamp adapter:	100 µm
Contact lens:	Mainster focal grid: (1.05x)
Power:	70 mW [reduced 70% from power used to achieve tissue reaction during the test burn]
Exposure duration:	200 ms
Duty cycle:	5%
Repetition rate:	
Treatment technique:	High density grid (painting) treatment over edematous area
Treatment endpoint:	None.
Evidence of laser treatment:	None at any time during or post treatment

1. Lavinsky D, Cardillo JA, Melo LA, Jr., Dare A, Farah ME, Belfort R Jr. Randomized clinical trial evaluating mETDRS versus normal or high-density micropulse photocoagulation for diabetic macular edema. Invest Ophthalmol Vis Sci 2011;52(7):4314-23.

Treatment techniques and opinions presented in this case report are those of the author. IRIDEX assumes no responsibility for patient treatment, outcome, or for physicians' negligence.

IRIDEX, IRIDEX logo are registered trademarks, and MicroPulse is a trademark of IRIDEX Corporation.